

**ANALYSIS OF THE BRODIE MANDIBLE,
ST. HELENA ISLAND, BEAUFORT COUNTY,
SOUTH CAROLINA**



CHICORA RESEARCH CONTRIBUTION 478

ANALYSIS OF THE BRODIE MANDIBLE, ST. HELENA ISLAND, BEAUFORT COUNTY, SOUTH CAROLINA

Prepared By:
Debi Hacker

CHICORA RESEARCH CONTRIBUTION 478



Chicora Foundation, Inc.
PO Box 8664
Columbia, SC 29202-8664
803/787-6910
www.chicora.org

September 18, 2007

This report is printed on permanent paper ∞

©2007 by Chicora Foundation, Inc. All rights reserved. No part of this publication may be reproduced, stored in a retrieval system, transmitted, or transcribed in any form or by any means, electronic, mechanical, photocopying, recording, or otherwise without prior permission of Chicora Foundation, Inc. except for brief quotations used in reviews. Full credit must be given to the authors, publisher, and project sponsor.

ABSTRACT

This brief report provides information on a human mandible recovered from the vicinity of Station Creek on St. Helena Island, Beaufort County, South Carolina. The mandible was loaned to Chicora for this analysis and was subsequently returned to the individual who found the remains.

The mandible is likely that of a female of European descent. The most likely source of the remains is an eroding family cemetery, although no information is available concerning its probable location.

TABLE OF CONTENTS

List of Figures		iv
List of Tables		iv
Analysis		1
<i>Introduction</i>	1	
<i>Results</i>	1	
<i>Conclusions</i>	3	
Sources Cited		5

LIST OF FIGURES

Figure

1. Portion of the Parris Island topographic map		1
2. Portion of the 1920 Fort Fremont topographic sheet	2	
3. View of the mandible from the left	2	
4. View of the mandible from the front		3
5. Left premolar and left canine	3	
6. Right premolar	3	

LIST OF TABLES

Table

1. Mandible measurements	3
--------------------------	---

ANALYSIS

Introduction

In July 2006, a mandible was received at the Chicora Foundation office from Mr. Steven H. Brodie of Atlanta, Georgia. He found the specimen circa 1959- 1960 on the beach of St. Helena's Island, close to the Station Creek end of the island, near Lands End. He commented that it was found at a time when there was still some remnant beach in front of Lands End. Today the erosion has almost completely removed the beach (Figure 1).

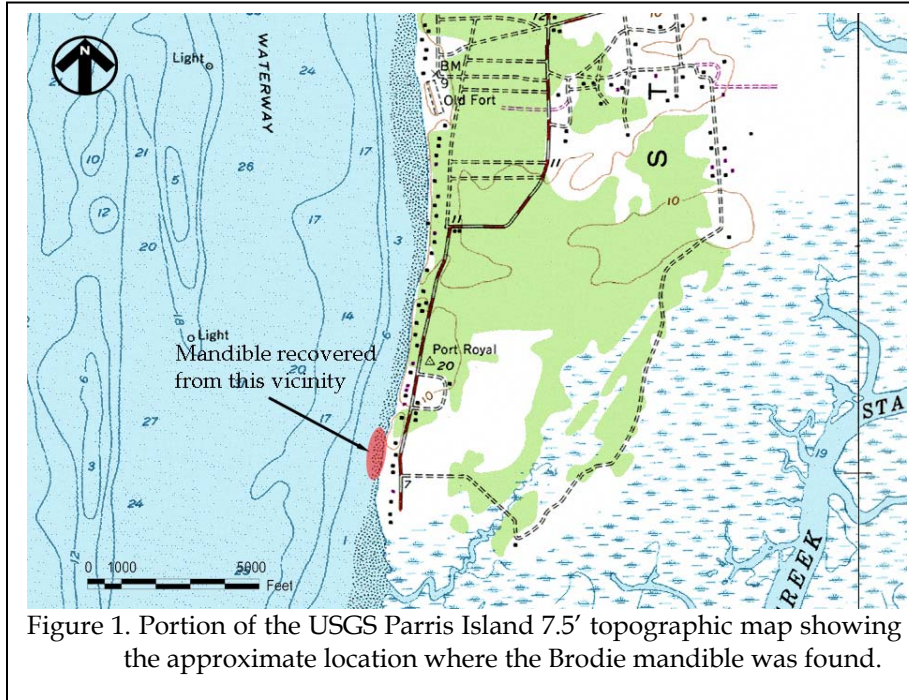


Figure 1. Portion of the USGS Parris Island 7.5' topographic map showing the approximate location where the Brodie mandible was found.

Figure 2 is a 1920 map of the same area showing the beach and a very significant bluff that previously existed. Although no archaeological research has been conducted in this area, Chicora's cartographic survey (Hacker and Trinkley 1992) identified a settlement in this approximate area, shown on maps dating from the second half of the nineteenth century.

The mandible was the only item found and Mr. Brodie sent the item to Chicora to learn more about it.

Results

The mandible was examined and measured by Debi Hacker at the Chicora lab on September 11, 2006.

The mandible is in good, stable condition.

The bone surface is a pale cream color, typical of aged bone. Seven teeth are missing postmortem, while three teeth remain in place. The mandibular condyles have broken off post-mortem. There is some minor erosion on the superior edges of the gonial angles, probably from the mandible sitting on a hard surface. The right canine has enamel broken off the tooth. The mandible has no remarkable formations; there is a single mental foramen on each side, there is a mylohyoid bridge present, and no mandibular torus.

Eight measurements and two estimated measurements were taken (Table 1). The maximum ramus breadth and height were estimated due to postmortem breakage to the mandibular condyles.

The gonial angle of 126 indicates that the mandible likely belonged to a female (male

ANALYSIS OF THE BRODIE MANDIBLE

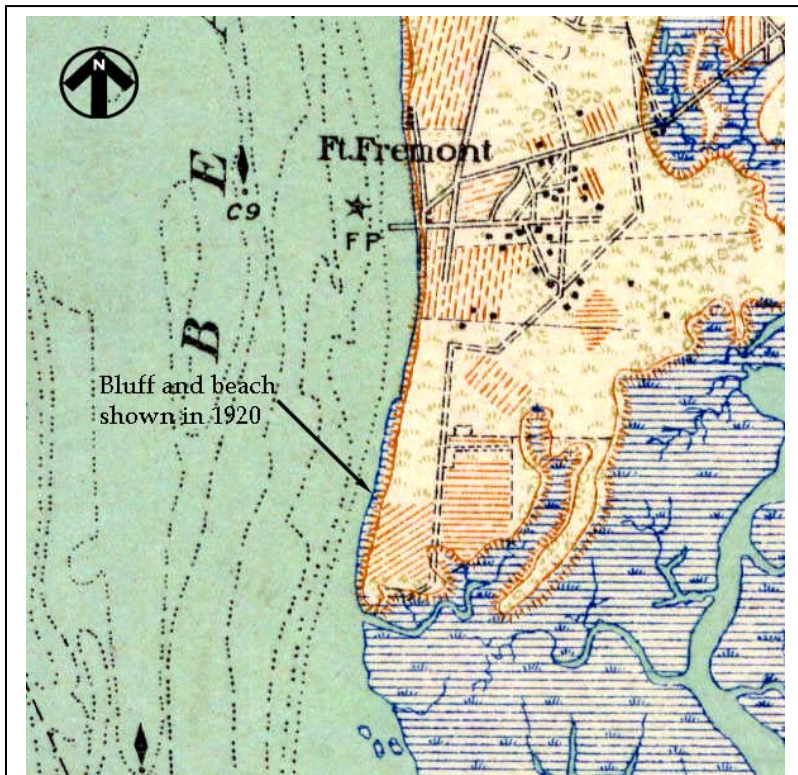


Figure 2. Portion of the 1920 Fort Fremont 15' topographic sheet.

measurement would be <124). The ascending ramus has a minimum breadth of 33.6mm, which is indicative of a male (male measurements are >33mm; female measurements are 28mm). These are the only measurements on the mandible that can be used for gender identification (Buikstra 1994).

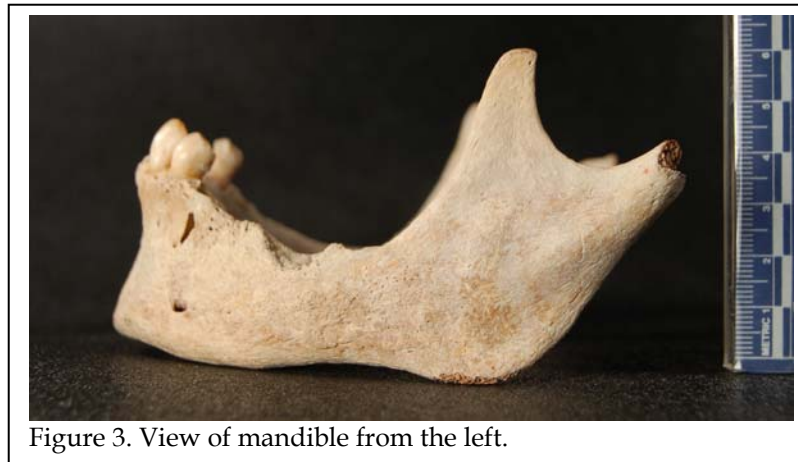

Figure 3. View of mandible from the left.

information. The mandible is generally small and gracile. The chin is pointed and small, indicating a female. The gonial eversion is slight, also indicating a female. The mental eminence has a very slight projection, indicative of a female. The bigonial breadth, in comparison to mandibles of known racial origin, is narrow, indicating a person of European descent.

There are only three teeth remaining with the mandible: a right premolar (28 P₁), a left premolar (21 P₁), and the left canine (22 C). There are no caries present, and no hypoplasia.

There is a moderate amount of calculus on the left premolar and canine. There is minimal wear on all teeth, in spite of so few existing antemortem, indicating a relatively young age. Although lost antemortem, the third molars had erupted, indicative of an age over 19-20 years (Bass 1995). The remaining teeth are small, indicating a female.

The most significant aspect of the mandible is the loss of teeth antemortem, and subsequent alveolar resorption. Two premolars and all molars were lost, with significant bone growth across the sockets. Based on degrees of alveolar resorption, it appears that the premolars and first and second molars were lost first, followed by the right third molar, then the left third molar. There is also significant bone change below the left premolar and canine. The presence of calculus, lack of caries, tooth loss, and significant alveolar resorption are indicative of serious periodontal disease (Ortner et al. 1981).

Non-metric traits provide more

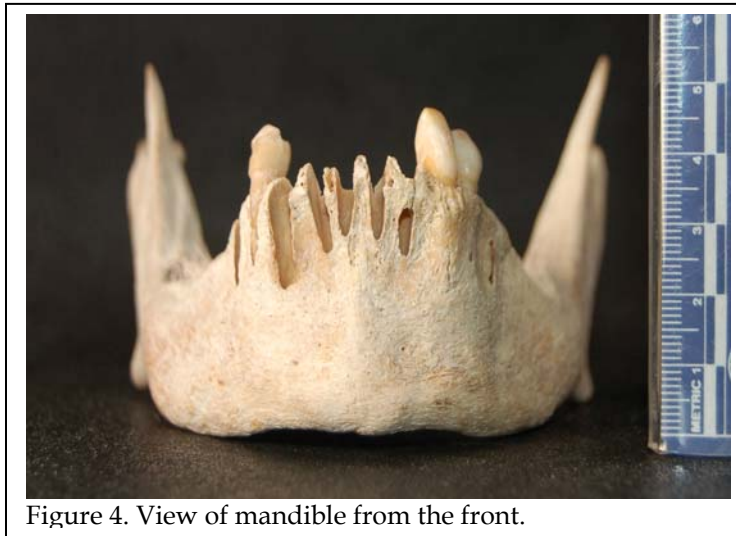


Figure 4. View of mandible from the front.

Conclusions

Although the metric measurements are non-conclusive for gender, all nonmetric traits

Table 1.
Mandible Measurements

Area measured	mm
Height of mandibular body	34.9
Breadth of mandibular body	10.6
Bigonial width	96.9
Bicondylar breadth	108.9
Minimum ramus breadth	33.6
Maximum ramus breadth	39.5*
Maximum ramus height	55.5*
Mandibular length	89.5
Height of mandibular synthesis	40.0
Mandibular angle	126

indicate that this mandible probably belonged to a female of European descent. The mandible is overall small and gracile, the teeth small, and the chin small and narrow.

The tooth development indicates that this person was over the age of twenty years, while the wear on the remaining teeth suggests a probable age of less than forty years. The loss of teeth and alveolar resorption indicates that the individual suffered from severe periodontal disease. No other

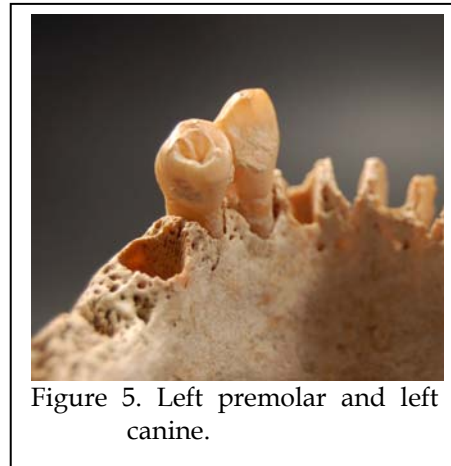


Figure 5. Left premolar and left canine.

indicators of disease were noted.

It is likely that the mandible eroded from a nineteenth Euro-American burial in

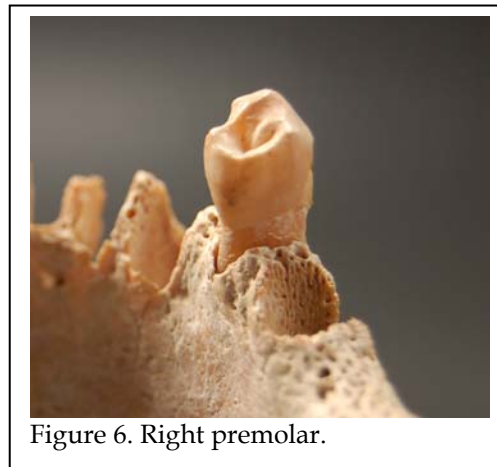


Figure 6. Right premolar.

the immediate area. Given the limited erosion of the mandible the displacement probably occurred only shortly before the item was collected from the beach.

SOURCES CITED

Bass, William M.

- 1995 *Human Osteology: A Laboratory and Field Manual*. Missouri Archaeological Society, Columbia, Missouri.

Buikstra, Jane E. and Douglas H. Ubelaker, editors

- 1994 *Standards for Data Collection from Human Skeleton Remains*. Arkansas Archeological Survey Research Series No. 44, Fayetteville.

Hacker, Debi and Michael Trinkley

- 1992 *Cartographic Survey of Historic Sites in Beaufort County, South Carolina*. Research Contribution 85. Chicora Foundation, Inc., Columbia.

Massler, Maury, and Isaac Schaur

- 1958 *Atlas of the Mouth in Health and Disease*. American Dental Association, Chicago.

Ortner, Donald J. and Walter G.J. Putschar

- 1985 *Identification of Pathological Conditions in Human Skeletal Remains*. Smithsonian Press, Washington, D.C.

